



# Most Number of Ureteric Stones Removal Ever Recorded Done Via Endoscopic Surgery

Hussain A\*

Specialist – Urology, LifeCare hospital, Musaffah, Abu Dhabi, UAE

\*Corresponding author: Hussain A, Specialist – Urology, Life Care hospital, Musaffah, Abu Dhabi, UAE

## Abstract

Surgical treatment of stone disease has evolved through generations of research and usage of various engineering models. Now at present we have many technological advances in the field of Endo Urological Management of Stone disease at our disposal.

**Keywords:** Endourological; Haemoglobin; Abdominal pain

## Introduction

Surgical treatment of stone disease has evolved through generations of research and usage of various engineering models. Now at present we have many technological advances in the field of Endo Urological Management of Stone disease at our disposal. Many of these advances has come as a boon to treat various cases of challenging stone situations. We describe one such challenging condition where surgical treatment of stone disease is always a Dilemma due to its various approaches to patient with Stone disease. We hereby describe a rare case of large number of ureteric stones load in a case of congenital ureterocele with megaureter, in a 33-year-old gentleman presenting with lower abdominal pain.

## Case

A 27-year-old Indian gentleman presented to us with dull aching pain in the lower abdomen and more on the left lower quadrant for the past 10 days. There was history of dysuria and hematuria. Clinical examination showed soft and non-distended abdomen with no tenderness, no palpable mass or organomegaly with intact hernial orifices. External genitalia examination revealed normal study. Investigations showed Hemoglobin of 14.7 gm%, S. Creatine 101mmol/L. WBC counts 9850 cell/cmm and Urine analysis shows – normal, RBC. USG revealed Dilated lower portion of left ureter with multiple calculi largest of them 24mm and lower pole calculi in left kidney and CT KUB done showed

Large dilated ureter left side with multiple calculi and left lower pole renal calculi.

## Pre-Operative Images

**Operation performed:** Cystoscopy + LASER incision of Left ureterocele + laser Lithotripsy + Double j stenting

**Procedure highlights:** Smiley incision using LASER. Dilated lower ureter with multiple calculi atleast 35-40 with large calculus 24mm.

**Intra Operative findings:** Postoperative recovery was uneventful. Patient improved well. Foleys catheter removal done on 1st day. .

## Discussion

Anomalous ureteric caliber with congenital ureterocele very rarely lead to compromised renal drainage with increase the risk of urolithiasis. Endourological management is challenging due to these abnormalities leading to difficulties accessing the stone. Treatment such as Ureterolithomy and stone extraction are described in literature for management of giant ureteric calculus but can be technically challenging, with associated morbidities. Advances in technology and technique have allowed us to use a different approach to this case. Here we have used the combination of Ureterscopy with help of holmium laser technology to access the stones via smiley incision over the base of the ureterocele and retrieval into the bladder. The bladder stones are removed by partial fragmentation of the stones using

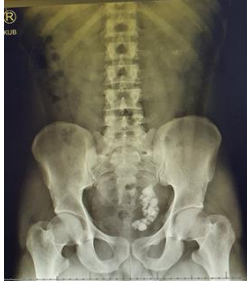**Received date:** 17 June 2023; **Accepted date:** 20 June 2023; **Published date:** 27 June 2023

**Citation:** Hussain A (2023) Most Number of Ureteric Stones Removal Ever Recorded Done Via Endoscopic Surgery. SunText Rev Case Rep Image 4(4): 189.

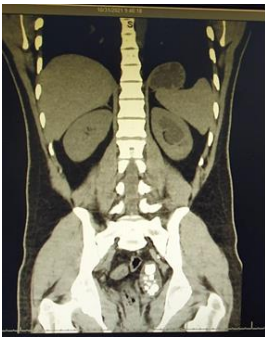
**DOI:** <https://doi.org/10.51737/2766-4589.2023.089>

**Copyright:** © 2023 Hussain A. This is an open-access article distributed under the terms of the Creative Commons Attribution License, which permits unrestricted use, distribution, and reproduction in any medium, provided the original author and source are credited.

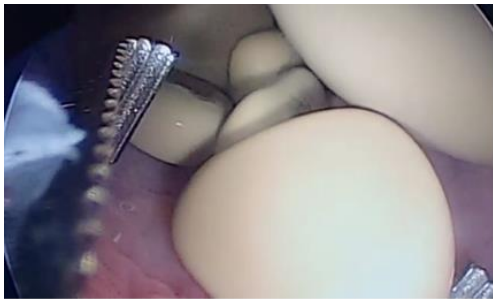nephroscope into the urethra and combination of Pneumatic lithoclast and holmium laser had immense value in retrieval of stone fragments via bladder. This article aims to review and summarise the efficacy and safety of holmium laser with URS for urolithiasis in anomalous ureter. This is the most number of stones removal documented in a single ureter in a single via total endoscopic approach (Figures 1-5) [1-5].



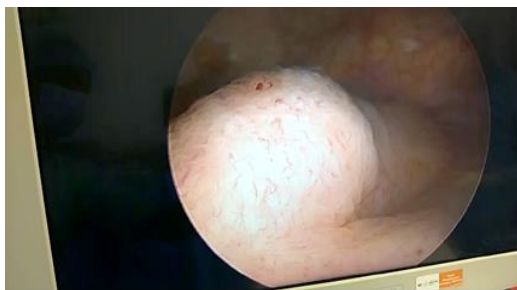
**Figure 1:** X-Ray KUB with left large ureteric stone bulk.



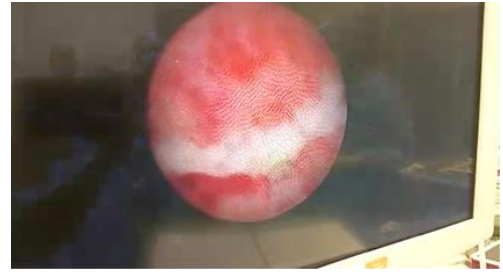
**Figure 2:** CT KUB sagittal image showing dilated left lower ureter with multiple.



**Figure 3:** Intra Op Picture of stone grasping from the dilated lower ureter.



**Figure 4:** Dilated left distal ureter with Ureterocele.



**Figure 5:** LASER incision of the left ureterocele.

## References

1. Turk C, Knoll T, Petrik A, Sarica K, Seitz C, Straub M. Guidelines on Urolithiasis. European Association Urol. 2021.
2. Gurbuz C, Atis G, Arikan O. Ureterscopy in anomalous ureteral anatomy: challenges and solutions. World J Urol. 2013; 31: 1457-1463.
3. Basiri A, Hosseini SR, Tousi VN. Endoscopic management of ureteral stones: Iranian experience. Urol J. 2005; 2: 41-46.
4. Turk H, Sahin A, Erkan E. Giant ureteral calculi: clinical considerations and therapeutic approaches. Urolithiasis. 2015; 43: 345-349.
5. Aron M, Goel R, Gautam G. Percutaneous management of large impacted upper ureteral calculi: techniques and results. Urol. 2004; 64: 644-648.