SUNTEXT REVIEWS

SunText Review of Case Reports & Images
ISSN: 2766-4589

Open Access
Case Report
Volume 7:2

Infantile Giant Left Cervico-Axillary Dumbbell Cystic Lymphangioma with Ipsilateral Upper-Limb Lymphedema

Khatri LK[1], More AB[2], Govani PS[3], Zaparackaite I[4], More BB[5], Singh SJ[6], Swamy KB[6], Mehta AR[7], Midha PK[7] and Patel RV[8,*]

[1]*Hon Clinical Fellow, Dept of Cardiothoracic surgery, Guys and St Thomas' NHS Foundation Trust, London, UK*
[2]*Dept of Ped |Surgery, Southampton General Hospital, UK*
[3]*Pearl women's Hospital and IVF center, Rajkot, India*
[4]*Dept of Ped Surg, Evelina Children's Hospital; London, UK*
[5]*Department of Pediatric Surgery, Nottingham University Hospitals, Nottingham, UK*
[6]*Lincoln Uni College, 2, Jalan Stadium, 47301 Petaling Jaya, Selangor, Malaysia*
[7]*J Watumull Global Hospital and Research Centre, Delwara Road, Mount Abu, Rajasthan, India*
[8]*Dept of Ped Surgery, PGICHR and KTCGUH, Rajkot, Gujarat India*

[*]**Corresponding author:** Patel RV, Director-Professor, Department of Pediatric Surgery, Postgraduate Institute of Child Health and Research and K T Children Government University Teaching Hospital, India; E-mail: ramnik@doctors.org.uk

Received date: 22 November 2026; **Accepted date:** 25 November 2026; **Published date:** 30 November 2026

Citation: Khatri LK, More AB, Govani PS, Zaparackaite I, More BB, Singh SJ, et al. (2026) Infantile Giant Left Cervico-Axillary Dumbbell Cystic Lymphangioma with Ipsilateral Upper-Limb Lymphedema. SunText Rev Case Rep Image 7(2): 177.

DOI: https://doi.org/10.51737/2766-4589.2026.177

Copyright: © 2026 Khatri LK, et al. This is an open-access article distributed under the terms of the Creative Commons Attribution License, which permits unrestricted use, distribution, and reproduction in any medium, provided the original author and source are credited.

Abstract

Background: Lymphatic malformations (cystic lymphangiomas or cystic hygromas) are congenital abnormalities of the lymphatic system that commonly occur in the cervicofacial region. Extension across anatomical compartments into the axilla with associated upper-limb lymphedema is uncommon and presents diagnostic and surgical challenges.

Case Presentation: An infant presented with a progressively enlarging soft cystic swelling involving the left side of the neck with extension into the axillary region, producing a dumbbell-shaped cervico-axillary mass. Associated diffuse swelling of the ipsilateral upper limb suggestive of congenital lymphedema was present. Clinical examination demonstrated a soft, compressible, non-pulsatile lesion without cutaneous discoloration. Ultrasound and color doppler imaging confirmed a multiloculated cystic lesion extending from the cervical region through the thoracic inlet towards the axilla. Complete surgical excision was performed through a cervical and axillary approach with careful preservation of neurovascular structures. Histopathological examination confirmed cystic lymphangioma. Postoperatively the infant recovered satisfactorily, with no evidence of recurrence during follow-up and improvement of limb swelling.

Conclusion: Cervico-axillary dumbbell lymphangioma associated with ipsilateral upper-limb lymphedema is an extremely uncommon presentation of lymphatic malformation. Complete excision remains an effective treatment when anatomically feasible. Awareness of associated lymphatic developmental abnormalities is important for appropriate management and long-term surveillance.

Keywords: Lymphangioma; Cystic hygroma; Lymphatic malformation; Cervico-axillary mass; Lymphedema; Infant; Paediatric surgery

Introduction

Lymphatic malformations, historically termed cystic lymphangiomas or cystic hygromas, are congenital vascular anomalies resulting from abnormal development of embryonic lymphatic channels and failure of communication with the central lymphatic system.

Approximately 75% occur in the head and neck region, whereas axillary involvement is considerably less frequent. Extensive lesions traversing both the cervical and axillary compartments to form a dumbbell-shaped mass are rare and may pose significant diagnostic and surgical challenges. Associated ipsilateral limb lymphedema is an uncommon finding and suggests a more widespread developmental abnormality of regional lymphatic drainage [1-4]. Modern classification systems recognize lymphatic malformations as distinct vascular anomalies requiring specialized multidisciplinary management [3,4]. Although advances in imaging and sclerotherapy have transformed treatment approaches, complete surgical excision remains an important therapeutic option in selected infants with large symptomatic lesions [4]. The senior author has previously reported a range of rare vascular and lymphatic disorders in childhood, including congenital bilateral internal jugular venous malformations, extensive central venous thrombosis associated with chylous complications, giant venous malformations and congenital lymphovascular disorders [5-8]. These experiences emphasize the diversity of developmental lymphatic abnormalities encountered in pediatric surgical practice. We describe a rare infant with a giant left cervico-axillary dumbbell complex cystic lymphangioma associated with ipsilateral upper-limb lymphedema, successfully managed by complete surgical excision. The unusual anatomical extent of the lesion and its association with congenital limb lymphedema make this case worthy of documentation.

Case Report

An infant was referred with a congenital swelling involving the left side of the neck extending towards the axilla. The lesion had gradually increased in size since birth. The infant demonstrated noticeable swelling of the entire left upper limb consistent with lymphatic dysfunction. Examination revealed a large soft, fluctuant, transilluminant mass occupying the left cervical region with extension into the axilla. The lesion was compressible and non-tender. There was no bruit, overlying skin discoloration, or evidence of acute infection. The ipsilateral upper limb was diffusely enlarged compared with the contralateral side. Preoperative ultrasound with color doppler imaging demonstrated a multiloculated cystic lesion extending through the cervico-axillary region without evidence of significant vascular invasion. A diagnosis of complex cervico-axillary lymphatic malformation was made. Surgical exploration revealed a multiloculated cystic lesion extending from the neck into the axilla, connected through a narrow component producing a dumbbell configuration. Meticulous dissection was required because of close proximity to major cervical vessels, the brachial plexus and axillary neurovascular structures. Complete excision was achieved. Histopathological examination demonstrated dilated endothelial-lined lymphatic channels containing proteinaceous lymphatic fluid, confirming cystic lymphangioma. The postoperative course was uneventful. Follow-up demonstrated satisfactory wound healing, no clinical recurrence and improvement in ipsilateral upper-limb swelling.

Discussion

Lymphatic malformations arise from sequestrated embryonic lymphatic tissue that fails to establish normal communication with the central lymphatic drainage system. These lesions are usually identified at birth or within the first two years of life and most commonly involve the cervicofacial region [4,9,10]. The present case is unusual because of the extensive cervico-axillary extension producing a dumbbell configuration and the coexistence of ipsilateral upper-limb lymphedema. This combination supports the concept of a regional developmental defect involving both lymphatic formation and lymphatic drainage pathways. Similar embryological mechanisms have been proposed for complex vascular malformations and congenital lymphatic disorders [1-4,9]. Clinical examination remains important, but modern imaging, particularly magnetic resonance imaging, is essential for defining lesion extent and its relationship to major vascular and neural structures [4,10]. Accurate anatomical delineation is particularly important in cervico-axillary lesions because of proximity to the carotid sheath, brachial plexus, thoracic duct, subclavian vessels and axillary neurovascular structures. The senior author's previous reports of congenital internal jugular venous malformations, extensive neonatal venous thrombosis with lymphatic complications, giant venous malformations and complex congenital vascular anomalies further illustrate the wide spectrum of developmental vascular disorders encountered in infancy and childhood [5-8]. Recognition of these

associations may assist clinicians in identifying underlying abnormalities affecting the entire regional lymphovascular system rather than a single isolated lesion (Figures 1-3).



Figure 1: *Preoperative clinical photograph demonstrating a large left cervico-axillary cystic lymphangioma with associated ipsilateral upper-limb enlargement.*



Figure 2: *Excised multiloculated cystic lymphangioma specimen showing the characteristic thin-walled cystic structure.*

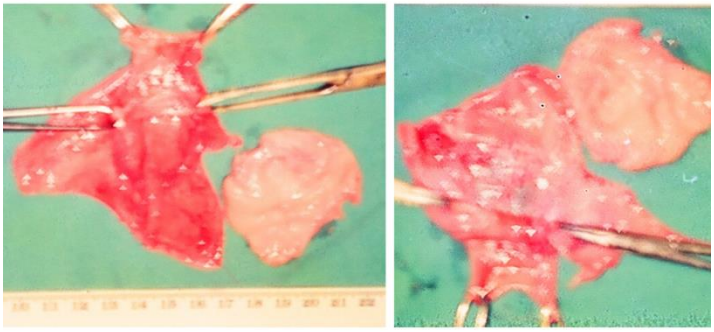

Figure 3: *Operative specimen following complete excision demonstrating the dumbbell configuration of the lesion.*

Although image-guided sclerotherapy has become increasingly popular for macrocystic lesions, complete surgical excision remains an effective treatment when safe dissection can be achieved [4,10,11]. Surgery offers immediate decompression, definitive histological diagnosis and reduced recurrence when complete excision is possible. However, incomplete resection may result in recurrence, particularly where lesions involve major neurovascular structures [11,12]. In our patient, meticulous surgical excision was successfully achieved despite the extensive cervico-axillary involvement. The associated upper-limb lymphedema improved following surgery, suggesting relief of regional lymphatic obstruction. Long-term follow-up remains important because recurrence and progression of associated lymphatic abnormalities have been reported even after apparently complete excision [10-12]. This case highlights the importance of recognizing unusual patterns of lymphatic malformation, undertaking detailed preoperative assessment and maintaining awareness of associated congenital lymphatic drainage disorders.

Conclusion

Left cervico-axillary dumbbell cystic lymphangioma associated with ipsilateral upper-limb lymphedema is a rare congenital lymphatic malformation. Careful preoperative assessment and meticulous surgical excision can achieve excellent outcomes. Recognition of associated lymphatic developmental abnormalities is essential for long-term follow-up and recurrence surveillance (Tables 1,2).

Table 1: *Management Options.*

Management options

1	2	3	4
Observation	**Sclerotherapy**	**Surgical excision**	**Medical therapy**
Small, asymptomatic lesions may be monitored.	Image-guided injection, mainly for macrocystic disease.	Complete removal, including satellite cysts, to limit recurrence.	Sirolimus is used for extensive or complex lesions.

Table 2: *Take Home Messages.*

Key takeaways

1	Lymphatic malformations are benign but can grow large in the neck and axilla.
2	Complete excision, including satellite cysts, reduces the risk of recurrence.
3	Treatment is matched to cyst type, size and location.

Acknowledgements

We are grateful to Dr Jitendra Govani, primary care and referring physician's consultant pediatricians Dr Kavita Govani and Dr Anil Trambadia, and the radiology and histopathology departments of our institution that contributed directly to the work

Author Contributions

LKK: Conceptualization, Investigation, Data Curation, Writing – Original Draft.
ABM: Investigation, Data Curation, Writing – Review & Editing.
PSG: Investigation, Literature Review, Data Curation.
IZ: Validation, Clinical Interpretation, Writing – Review & Editing.
BBM: Clinical Supervision, Validation, Writing – Review & Editing.
SJS: Conceptualization, Supervision, Validation, Writing – Review & Editing.
KBS: Methodology, Anatomical Interpretation, Writing – Review & Editing.
ARM: Validation, Clinical Interpretation, Writing – Review & Editing.
PKM: Validation, Clinical Interpretation, Writing – Review & Editing.
RVP: Conceptualization, Literature Review, Supervision, Project Administration, Writing – Original Draft, Writing – Review & Editing.

Ethics Statement

Written informed consent for publication of clinical information and images was obtained from the patient's parent or legal guardian.

Conflict of Interest

The author declares no conflict of interest.

Funding

No funding was received.

Data Availability

All relevant data are included within the manuscript.

References

1. Patel RV, Curry JI, Sinha CK, Davenport M. Vascular anomalies. In: Sinha CK, Davenport M, editors. Handbook of Pediatric Surgery. 2nd edn. Cham: Springer. 2024.
2. Patel R, Curry JI. Vascular malformations. In: Sinha CK, Davenport M, editors. Handbook of Pediatric Surgery. 1st ed. London: Springer; 2010; 221-228.
3. Wassef M, Blei F, Adams D, Alomari A, Baselga E, Berenstein A, et al. Vascular anomalies classification: recommendations from the international society for the study of vascular anomalies. Pediatr. 2015; 136: e203-e214.
4. Elluru RG, Balakrishnan K, Padua HM. Lymphatic malformations: diagnosis and management. Semin Pediatr Surg. 2014; 23: 178-185.
5. Patel RV, Horton D, Robinson G, Lakshminarayan R, Daniel R. Congenital bilateral internal jugular venous malformation in an infant with spinal osteomyelitis and discitis: nature's recipe for disaster at vascular access. J Pediatr Surg Specialties. 2016; 10: 28-33.
6. Patel R, Griselli M, Barrett AM. Congenital extensive central venous thrombosis with chylous ascites and chylothoraces. J Pediatr Surg. 2013; 48: e5-e8.
7. Patel RV, Govani DJ, Govani ND, Govani DR, Panchasara NG, Patel RR, et al. Giant cavernous vascular venous malformation of the glans and distal penile shaft in a toddler treated successfully with steroids followed by circumcision. MedP J Cardiol Vasc Med. 2022; 2.
8. Sinha A, Patel RV, Sinha CK. Giant infantile abdominoscrotal hydrocele with giant blue leg: all that glitters is not gold in an infantile hydrocele. J Ind Med Assoc. In press. Manuscript ID: JIMA11112992.
9. Mulliken JB, Glowacki J. Hemangiomas and vascular malformations in infants and children: a classification based on endothelial characteristics. Plast Reconstr Surg. 1982; 69: 412-422.
10. Perkins JA, Manning SC, Tempero RM, Cunningham MJ, Edmonds JL, Hoffer FA, et al. Lymphatic malformations: current cellular and clinical investigations. Otolaryngol Head Neck Surg. 2010; 142: 789-794.
11. Smith RJH, Burke DK, Bauman NM. Lymphatic malformations of the head and neck in children. Otolaryngol Clin North Am. 1998; 31: 521-531.
12. Kennedy TL. Cystic hygroma-lymphangioma: a rare and still unclear entity. Laryngoscope. 1989; 99: 1-10.